

ANALGESIC EFFECT OF EXTRACORPOREAL SHOCK-WAVE THERAPY ON CHRONIC TENNIS ELBOW

JAN D. ROMPE, CHRISTOF HOPF, KLAUS KÜLLMER, JOCHEN HEINE, RAINER BÜRGER

From Johannes Gutenberg University Hospital, Mainz, Germany

We report a controlled, prospective study to investigate the effect of treatment by low-energy extracorporeal shock waves on pain in tennis elbow. We assigned at random 100 patients who had had symptoms for more than 12 months to two groups to receive low-energy shock-wave therapy. Group I received a total of 3000 impulses of 0.08 mJ/mm² and group II, the control group, 30 impulses.

The patients were reviewed after 3, 6 and 24 weeks. There was significant alleviation of pain and improvement of function after treatment in group I in which there was a good or excellent outcome in 48% and an acceptable result in 42% at the final review, compared with 6% and 24%, respectively, in group II.

J Bone Joint Surg [Br] 1996;78-B:233-7.

Received 30 November 1994; Accepted after revision 17 November 1995

Although tennis elbow was first described more than 100 years ago its aetiology and pathophysiology remain uncertain (Ernst 1992; Foley 1993). The best method of treatment has not been established (Labelle et al 1992) and both conservative (Mucha and Wannske 1989; Haker and Lundberg 1991) and operative regimes (Wittenberg, Schaal and Muhr 1992; Verhaar et al 1993) have been advocated.

Low-dose extracorporeal shock-wave therapy has been found to be effective in treating persistent elbow pain in isolated cases. In this form of hyperstimulation analgesia, pain is alleviated by a moderate-to-intense sensory input

which is usually applied at the site of greatest discomfort for a period ranging from a few seconds to 20 or 30 minutes. This may relieve chronic pain for days, weeks and sometimes permanently (Melzack 1989).

We have studied the use of this treatment in patients with tennis elbow.

PATIENTS AND METHODS

Over a three-year period we treated 115 patients with lateral elbow pain by low-dose extracorporeal shock-wave therapy. During the first six weeks 15 patients discontinued the treatment leaving 100 who completed the full course.

Patients were included in the study if they had had pain in the lateral epicondyle for more than 12 months and had received unsuccessful conservative therapy in the previous six months. In addition, the pain had to be induced by two or more of the following tests:

- 1) Palpation of the lateral epicondyle.
- 2) Resisted wrist extension (Thomsen test). With the shoulder flexed to 60°, the elbow extended, the forearm pronated and the wrist extended about 30°, pressure is applied to the dorsum of the second and third metacarpal bones in the direction of flexion and ulnar deviation to stress the extensor carpi radialis brevis and longus.
- 3) Resisted finger extension. With the shoulder flexed to 60°, the elbow extended, the forearm pronated and the fingers extended the middle finger is actively extended against resistance.
- 4) Chair test. With the shoulder flexed to 60° and the elbow extended the patient attempts to lift a chair weighing 3.5 kg.

Patients were excluded if they were under 18 years of age or had dysfunction of the shoulder, neck and/or thoracic region, local arthritis, generalised polyarthritis, neurological abnormalities, radial-nerve entrapment, pregnancy, infection or malignancy, or a reduced range of movement at the elbow.

No other treatment was given for the six weeks before the shock-wave therapy began or during the course of this treatment.

The patients were randomly assigned to two groups. Group I consisted of 50 patients (30 women and 20 men) with a mean age of 43.9 years (26 to 61) and a mean duration of pain of 24.8 months (10 to 120). Group II comprised 50 patients (28 women and 22 men) with a mean

J. D. Rompe, MD, Senior Physician
C. Hopf, MD, Assistant Medical Director
K. Küllmer, MD, Resident
J. Heine, MD, Head
Orthopaedic University Hospital

R. Bürger, MD, Assistant Medical Director
Urological University Hospital
Johannes Gutenberg University Hospital, Langenbeckstrasse 1, D-55131
Mainz, Germany.

Correspondence should be sent to Dr J. D. Rompe.

©1996 British Editorial Society of Bone and Joint Surgery
0301-620X/96/21161 \$2.00

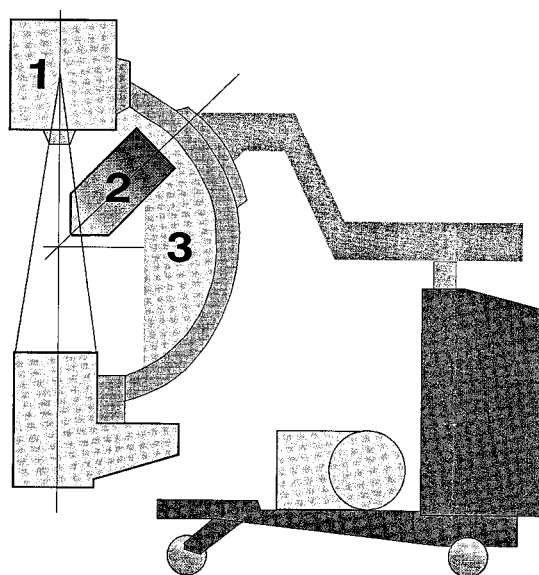


Fig. 1a

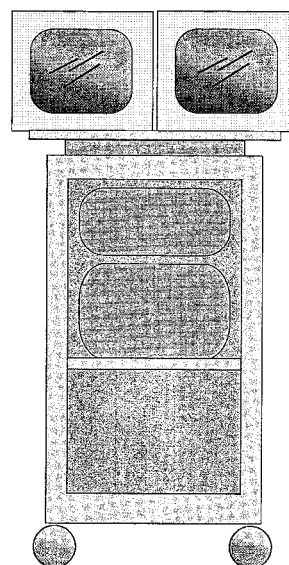


Fig. 1b

Diagram of the shock-wave unit (a) and screen (b) (1, arch; 2, shock-wave generator; 3, laser beam).

age of 41.9 years (26 to 58) and a mean duration of pain of 21.9 months (10 to 46). Both groups were treated under the same conditions and the patients were seen singly to avoid influencing one another. Three episodes of treatment consisting of either 1000 impulses of 0.08 mJ/mm^2 (group I) or 10 impulses of 0.08 mJ/mm^2 (group II) were administered at the anterior aspect of the lateral epicondyle and at three points around this site at a radius of 1.5 to 2 cm at a frequency of 3 Hz at intervals of one week. No local anaesthesia was used. Each session of treatment lasted for 20 to 30 minutes and none of the patients was unable to tolerate the discomfort produced by the shock waves. The patients were reviewed at 3, 6 and 24 weeks after the last application of the treatment.

Treatment. The extracorporeal shock-wave therapy is applied by an experimental device, the Siemens Osteostar (Siemens AG, Erlangen, Germany), in which an electromagnetic shock-wave generator is integrated into a mobile fluoroscopy unit (Fig. 1). Shock waves are generated by passing a strong electric current through a flat coil. This induces a magnetic field, which itself induces another magnetic field in a metal membrane overlying the flat coil. Just as similar poles repel each other, so do the generated magnetic fields of the membrane and the coil.

By means of an acoustic lens the source of the shock wave is focused at the centre of the C-arm. The focal area of the shock wave is defined as the area in which 50% of the maximum energy is reached. It has a length of 50 mm in the direction of the axis of the shock wave and a radius of 3.5 mm perpendicular to this. The C-arm is centred on the lateral epicondyle and the shock-wave unit linked to the

elbow by means of a water-filled cylinder (Rompe et al 1995). Ultrasound gel is used as a contact medium between the cylinder and the skin (Fig. 2).

Method of evaluation. The extent of pain was determined by a visual analogue scale ranging from 0 (no pain) to 100 (maximal pain). Examination was carried out independent-

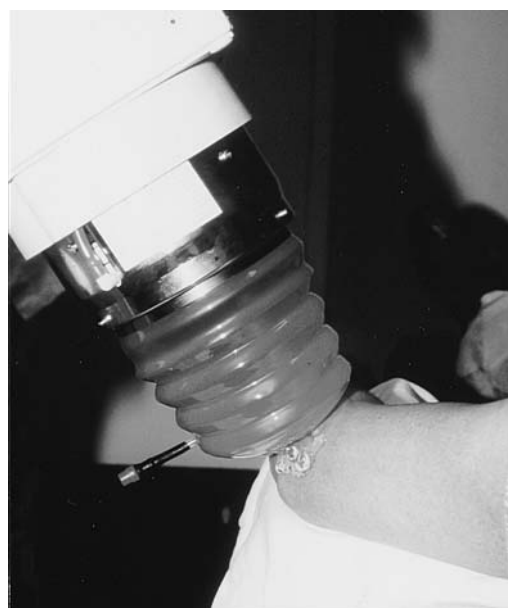

Fig. 2

Extracorporeal shock-wave therapy applied to the elbow.

Table I. Mean (SD) pain scores for all the tests in both groups before and at 0, 3, 6 and 24 weeks after treatment by low-dose extracorporeal shock-wave therapy

	Before treatment		After treatment (weeks)												
	-6 wks		0		3		6		24						
	Group I	Group II	p value	Group I	Group II	p value	Group I	Group II	p value	Group I	Group II	p value			
Night pain	32.5 (17.3)	29.9 (15.6)	>0.05	34.6 (15.8)	31.2 (16.0)	>0.05	13.2 (9.9)	34.6 (17.6)	<0.001	7.7 (8.8)	35.1 (18.1)	<0.001	7.3 (8.7)	32.5 (17.4)	<0.001
Resting pain	33.3 (22.0)	25.8 (14.7)	>0.05	37.3 (24.2)	27.3 (16.8)	>0.05	15.3 (10.5)	30.8 (19.4)	<0.001	14.8 (15.5)	33.8 (19.8)	<0.001	11.9 (14.7)	33.3 (22.0)	<0.001
Pressure pain	58.8 (16.5)	55.6 (13.1)	>0.05	63.6 (16.0)	60.7 (16.7)	>0.05	33.1 (11.7)	60.2 (17.0)	<0.001	26.9 (14.0)	59.8 (15.3)	<0.001	22.6 (15.8)	58.1 (15.2)	<0.001
Thomsen test	53.2 (16.1)	49.2 (13.0)	>0.05	54.7 (16.4)	52.8 (14.1)	>0.05	29.0 (16.4)	53.5 (14.2)	<0.001	25.2 (15.4)	57.4 (12.8)	<0.001	21.2 (16.4)	50.5 (16.9)	<0.001
Finger extension	55.8 (16.9)	51.8 (14.9)	>0.05	54.8 (17.6)	55.4 (12.9)	>0.05	29.8 (11.1)	60.9 (12.2)	<0.001	24.0 (13.8)	62.8 (12.3)	<0.001	20.1 (13.3)	60.1 (14.8)	<0.001
Chair test	46.0 (18.1)	48.9 (17.0)	>0.05	48.7 (19.9)	52.9 (16.7)	>0.05	24.8 (17.5)	51.2 (15.1)	<0.001	20.9 (14.8)	53.8 (14.0)	<0.001	16.7 (14.4)	52.7 (14.6)	<0.001

Table III. Mean (SD) values for grip strength in both groups before and at 0, 3, 6 and 24 weeks after treatment

	Before treatment		After treatment (weeks)												
	-6 wks		0		3		6		24						
	Group I	Group II	p value	Group I	Group II	p value	Group I	Group II	p value	Group I	Group II	p value			
Grip strength	2.4 (1.0)	2.4 (0.8)	>0.05	2.7 (1.1)	2.6 (0.9)	<0.05	1.8 (0.8)	2.4 (0.7)	<0.001	1.7 (0.7)	2.4 (0.8)	<0.001	2.0 (1.0)	2.4 (1.0)	<0.001

ly of the treating physician and included the same four diagnostic tests which had determined entry to the study. Grip strength was measured bilaterally by a vigorimeter which is a dynamometer with a rubber balloon which can be compressed by hand. Air pressure within the balloon was registered in kp/cm^2 . The classification of grip strength was as described by Mucha and Wannske (1989) in which: 1 = equal strength on both sides; 2 = up to 25% reduction of grip strength compared with the unaffected side; 3 = up to 50% reduction of grip strength compared with the unaffected side; and 4 = up to 75% reduction of grip strength compared with the unaffected side. Night and resting pain were also recorded.

At the end of follow-up all the patients were asked to assess their level of residual pain compared with before treatment according to the criteria of Roles and Maudsley (1972) as follows:

- 1) excellent – no pain, full movement, full activity;
- 2) good – occasional discomfort, full movement, full activity;
- 3) acceptable – some discomfort after prolonged activities; and
- 4) poor – pain-limiting activity.

The Wilcoxon-test of two independent samples and Fisher's exact test were used for statistical analysis.

RESULTS

In patients in group I there was a significant decrease in the level of pain recorded on the visual analogue scale compared with that in group II at each follow-up (Table I). The mean change in the pain score at the end of the study compared with the beginning is shown in Table II. There was a significant increase in grip strength in group I (Table III). Table IV shows the overall outcome. There were 24

good or excellent results in group I compared with only 3 in group II at the end of the study. Five patients in group I were regarded as failures compared with 35 in group II.

DISCUSSION

Although the diagnosis of tennis elbow may be fairly straightforward, management is often difficult (Geoffroy, Yaffe and Rohan 1994) and many different treatments have been suggested (Chard and Hazleman 1989). Ultrasound (Stratford et al 1989; Ebenbichler and Resch 1994), ionisation (Grossi et al 1986) and low-dose laser therapy (Ernst and Fialka 1992) have produced only placebo effects. Steroid injections have been shown to be beneficial (Day, Govindasamy and Patnaik 1978) but had failed in our patients, 92% of whom had received at least one steroid injection in the lateral epicondyle.

In the early part of this decade the use of extracorporeal shock-wave therapy was reported for conditions other than stones in the renal and biliary tracts, with encouraging results in the treatment of pseudarthroses and calcifying tendinitis of the shoulder (Dahmen et al 1992; Valchanou and Michailov 1991; Haist et al 1992; Kaulesar-Sukul et al 1993; Loew and Jurgowski 1993). Since 1991 we have gathered experience in the treatment of chronic pain at the elbow, heel and shoulder (Rompe et al 1955a,b) and promising results led to this prospective study. The shock waves are used to provoke painful levels of stimulation to relieve pain, by so-called hyperstimulation analgesia (Melzack 1975).

Animal studies have shown that tendons exposed to extracorporeal shock waves of such low-energy density do not show histological changes and damage to tendons is only observed after the application of high-energy shock waves. We have seen no complications in more than 500 patients so treated.

The mechanism of the analgesia produced by low-energy shock-wave therapy is uncertain. Control of pain by intense stimulation is ascribed to brain-stem mechanisms which exert a descending inhibitory control of transmission through the dorsal horns as well as at higher levels in the somatic projection system. The intense input is said to activate fibres of small diameter which project to cells in the periaqueductal grey areas. These in turn activate a serotonergic system which ultimately modulates transmission through the dorsal horns. The entire system is a

Table II. Mean percentage (SD) change in the pain score in both groups for all tests after 24 weeks

	Group I	Group II	p value
Night pain	-78.9 (22.4)	+4.0 (7.3)	<0.001
Resting pain	-68.1 (18.5)	+21.9 (18.1)	<0.001
Pressure pain	-64.5 (18.1)	-4.3 (10.6)	<0.001
Thomsen test	-61.2 (20.8)	-4.4 (9.4)	<0.001
Finger extension	-63.3 (19.7)	+8.5 (8.0)	<0.001
Chair test	-65.7 (19.1)	-0.3 (7.8)	<0.001

Table IV. Overall outcome in both groups at 3, 6 and 24 weeks after treatment

	3 weeks		6 weeks		24 weeks	
	Group I	Group II	Group I	Group II	Group I	Group II
Excellent	11	-	10	-	11	-
Good	16	10	16	6	13	3
Acceptable	18	16	18	10	21	12
Poor	5	24	6	34	5	35

complex feedback loop in which small-fibre inputs comprise the feedforward segment while the descending inhibitory system is the feedback (Melzack 1989).

Our success with this new method of treatment warrants further study of the most efficient method of its use and the mechanism of its influence on pain.

No benefits in any form have been received or will be received from a commercial party related directly or indirectly to the subject of this article.

REFERENCES

- Chard MD, Hazleman BL.** Tennis elbow: a reappraisal. *Br J Rheumatol* 1989;28:186-90.
- Dahmen GP, Meiss L, Nam VC, Skruodis B.** Extrakorporale Stosswellentherapie (ESWT) im knochenahen Weichteilbereich an der Schulter. *Extracta Orthopaedica* 1992;15:25-8.
- Day BH, Govindasamy N, Patnaik R.** Corticosteroid injections in the treatment of tennis elbow. *Practitioner* 1978;220:459-62.
- Ebenbichler G, Resch KL.** Critical evaluation of ultrasound therapy. *Wien Med Wochenschr* 1994;144:51-3.
- Ernst E.** Conservative therapy for tennis elbow. *Br J Clin Pract* 1992;46:55-7.
- Ernst E, Fialka V.** Low-dose laser therapy: critical analysis of clinical effect. *Schweiz Med Wochenschr* 1992;123:949-54.
- Foley AE.** Tennis elbow. *Am Fam Physician* 1993;48:281-8.
- Geoffroy P, Yaffe MJ, Rohan I.** Diagnosing and treating lateral epicondylitis. *Can Fam Physician* 1994;40:73-8.
- Grossi E, Monza GC, Pollavini S, Bona L.** NSAID ionisation in the management of soft-tissue rheumatism: role played by the drug, electrical stimulation and suggestion. *Clin Exp Rheumatol* 1986;4:265-7.
- Haist J, Steeger D, Witzsch U, Bürger RA, Haist U.** *The extracorporeal shockwave therapy in the treatment of disturbed bone union.* 7th Int Conference on Biomedical Engineering, Singapore, 1992:222-4.
- Haker E, Lundeberg T.** Is low-energy laser treatment effective in lateral epicondylalgia? *J Pain Symptom Manage* 1991;6:241-6.
- Kaulesar-Sukul DM, Johannes EJ, Pierik EG, van Eijck GJ, Kristelijn MJ.** The effect of high energy shock waves focussed on cortical bone: an in vitro study. *J Surg Res* 1993;54:46-51.
- Labelle H, Guibert R, Joncas J, et al.** Lack of scientific evidence for the treatment of lateral epicondylitis of the elbow: an attempted meta-analysis. *J Bone Joint Surg [Br]* 1992;74-B:646-51.
- Loew M, Jurgowski W.** Initial experiences with extracorporeal shock-wave lithotripsy (ESWL) in treatment of tendinosis calcarea of the shoulder. *Z Orthop Ihre Grenzgeb* 1993;131:470-3.
- Melzack R.** Prolonged relief of pain by brief, intense transcutaneous somatic stimulation. *Pain* 1975;1:357-73.
- Melzack R.** Folk medicine and the sensory modulation of pain. In: Wall PD, Melzack R, eds. *Textbook of pain.* Edinburgh, etc: Churchill Livingstone, 1989.
- Mucha C, Wannske M.** Ergebnisse einer kontrollierten Studie zur physikalischen Therapie der Epicondylopathia humeri. *Physik Ther* 1989;10:564-73.
- Roles NC, Maudsley RH.** Radial tunnel syndrome: resistant tennis elbow as a nerve entrapment. *J Bone Joint Surg [Br]* 1972;54-B:499-508.
- Rompe J-D, Hopf C, Eysel P, et al.** Extrakorporale Stosswellentherapie des therapieresistenten Tennisellenbogens: erste Ergebnisse von 150 Patienten. In: Chaussy C, Eisenberger F, Jocham D, Wilbert D, eds. *Die Stosswelle Forschung und Klinik.* Tübingen: Attempto Verlag Tübingen GmbH, 1995a;147-52.
- Rompe JD, Rumler F, Hopf C, Nafe B, Heine J.** Extracorporeal shock wave therapy for calcifying tendinitis of the shoulder. *Clin Orthop* 1995b;321:196-201.
- Stratford PW, Levy DR, Gaudie S, Miseferi D, Levy K.** The evaluation of phonophoresis and friction massage as treatments for extensor carpi radialis tendinitis: a randomized controlled trial. *Physiotherapy Canada* 1989;41:93-9.
- Valchanou VD, Michailov P.** High energy shock waves in the treatment of delayed and nonunion of fractures. *Int Orthop* 1991;15:181-4.
- Verhaar JAN, Walenkamp G, Kester A, Van Mameren H, Van der Linden T.** Lateral extensor release for tennis elbow: a prospective long-term follow-up study. *J Bone Joint Surg [Am]* 1993;75-A:1034-43.
- Wittenberg RH, Schaal S, Muhr G.** Surgical treatment of persistent elbow epicondylitis. *Clin Orthop* 1992;278:73-80.